

EPILEPSY SURGERY IN PEDIATRIC POPULATION SURGICAL RESULTS AND PREDICORS OF OUTCOME

CHAFIK HANDIS¹, M.D, NEUROSURGEON
BAHATTIN TANRIKULU¹, M.D, FEBNS. M. MEMET ÖZEK¹,
M.D, C. HANDIS²

1) Acibadem University School of Medicine, Depratment of Neurosurgery,
Division of Pediatric Neurosurgery, Istanbul / TURKEY

2) Dr. Chafik Handis attends pediatric neurosurgery fellowship program in our department which is sponsored by KARL STORZ Company. We have no other conflict of interest to declare. This work has not been presented, submitted or published anywhere.

ABSTRACT : **Introduction :** Drug-resistant epilepsy in children is a common pathology, having deleterious effects on cognitive and learning functions. After attempting different antiepileptic medication (AED) for treatment, surgery is indicated in patients with a refractory profile. Our objective is to report different statistical parameters of our patients, results of surgical techniques and define some predictors of outcome. **Methods:** We reviewed retrospectively 96 pediatric patients operated in our institution between 2005 and 2019, and analyzed several demographics and epilepsy parameters in order to define prognostic factors. Surgical techniques, histopathology of lesions were also included in our investigation. **Results:** The study population was composed of 96 patients; 63 male (65.6%), 33 female (34.4%). Median age at seizure onset was 2 years (range: 1 day-15 years). Median age at surgery was 7.3 years (range: 3 months-18 years). Mean duration of seizures was 4.3 years (range: 10 days-17 years). Median follow up was 4.9 years (range: 4 months-13.7 years). The best results regarding seizures were obtained in resective surgery group. The age of epilepsy onset was the important prognostic factor of outcome. **Conclusion:** Surgery is an effective therapeutic modality for refractory epilepsy in children, without mortality and/or a significant morbidity. Earlier onset of seizures is one of the bad prognosis factors that must be considered before surgical procedures.

Key words : Refractory epilepsy, surgery, drug resistant.

INTRODUCTION

The adequate definition that can be attributed for «intractable epilepsy» is the one that was conceived by the international league against epilepsy (ILAE) commission, as ; «the failure of two tolerated, well-chosen, and strictly used antiepileptic drugs (AED), as monotherapy or associated with another, to complete a maintained relief of seizures [20].

The median incidence of epilepsy in patient younger than 14 years old, is 82/100 000. This incidence is much lower for other ages and without a significant sex predilection [18].

In addition to medical treatment, the ketogenic diet is another therapeutic option that was observed to own antiepileptic proprieties in the early 20th century [2, 3], subsequently abandoned with the advent of anticonvulsant drugs such as example Phenytoin in 1938 [3].

This diet has proven its utility recently (during the last 30 years) in different centers

of the world [3] for both populations ; pediatric [23] and adult [4, 21].

After the inefficiency of these various therapeutic modalities , surgery remains the only option for management, which is the case of 30% of all patients [12]. The adverse effects of intractable epilepsy on the motor and mental development of a child's brain have propelled further the surgical options in the pediatric population.

Our aim is to share different data of 96 pediatric patients with drug-resistant epilepsy, operated in our clinic between 2005 and 2019, report long term results of surgery for this population and define the prognostic factors of outcome.

MATERIALS AND METHODS

In this retrospective study, we reviewed the medical data of 96 pediatric patients with drug-resistant epilepsy who were operated at Acibadem University, School of Medicine, Epilepsy Surgery Clinic between 2005 and 2019.

Patient evaluation before surgery :

All drug-resistant patients were evaluated using these explorations:

1- 3 TESLA MRI IMAGING PROTOCOL INCLUDING :

Sagittal and axial section turbo spin echo (TSE) T2-weighted imaging, coronal section fat-sat TSE T2-weighted diffusion, sagittal section three-dimensional 3D Turbo-FLAIR T2 with reconstructions, sagittal section 3D turbo flash T1 with reconstructions, and

axial section 3D susceptibility-weighted imaging and diffusion tensor imaging tractography (Fig. 1).

2- VIDEO EEG:

– Mode : at least ; for 48 hours and 3 ictal recordings (Fig. 2) : video EEG laboratory and working team) .

– Interest : analyze electrical brain activity and clinical behavior of the seizure and identify the focus of seizures .

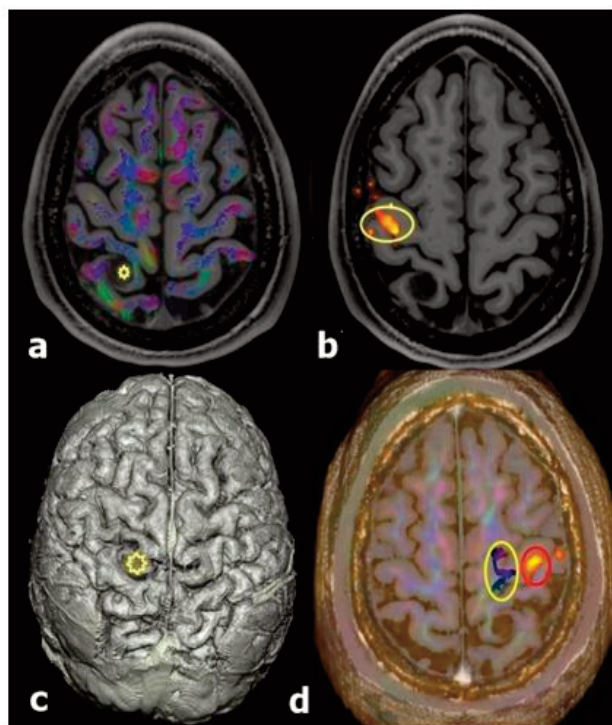


Fig. 1 : a:Tractography MRI sequence for a patient with refractory epilepsy, showing a tumor (DNET= yellow star), close to the motor cortex.

Notice white matter fibers with other colors(blue-green).b:Functional MRI(fMRI) of the same patient .

The motor activity is within the yellow circle in this image.c: 3D MRI reconstruction with the localization of the tumor (yellow star). d:combined tractography and functional MRI sequences: the proximity of the right motor cortex (red circle) and corticospinal tract (yellow circle) to the tumor location(backward).

After collecting data for all patients, the indication for surgery is discussed by a multi-disciplinary team composed of two pediatric neurosurgeons, a pediatric epileptologist, a neuroradiologist, and a clinical pediatric psychologist.

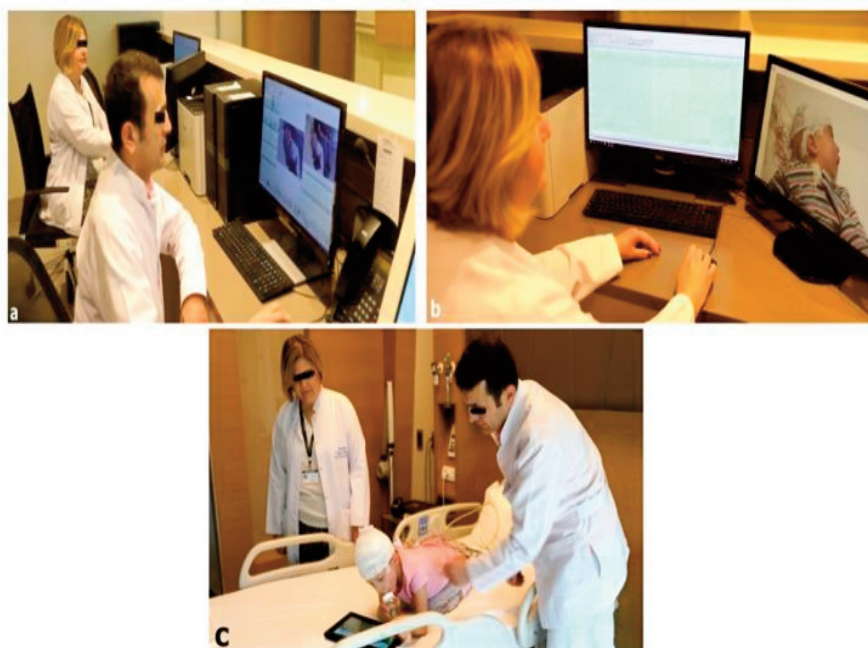

Figure 2 : images showing EEG laboratory (a,b) and the working team (pediatric epileptologist and EEG technician).c: patient having EEG recording after subdural grids insertion.

3- A CLINICAL ASSESSMENT BY A PEDIATRIC psychologist working with the pediatric neurosurgery team.

Some exceptions were considered for patients without a well-defined epileptic zone; the exploration was completed by additional nuclear medicine evaluations such as single-photon emission computerized tomography (SPECT) and positron-emission tomography (PET) (Fig. 3).

SURGICAL PROCEDURES

The all of patients had surgical targeted resection of the epileptic zone and lesions of different natures such as: cortical tubers,

neoplasm (Fig. 4 ; illustrates a case of DNET resection for one of the patients) or in some cases infarcted territory.

In cases where the epileptic network had an extension toward eloquent regions (motor cortex), multiple subpial transections (MSTs) were performed to preserve motor functions.

All patients with resective surgery had electrocorticography (ECoG) during the surgical procedures.

For some patients, decision-making for surgery was complicated because of the poor definition of the epileptic zone in term of boundaries. In this group, we proceeded with invasive recording (Fig. 5, 8).

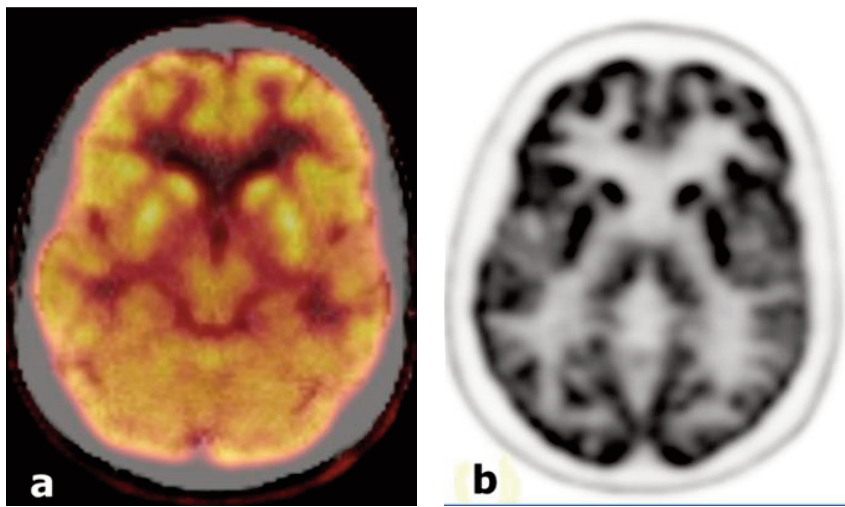


Figure 3 : Positron emission tomography CT (PET-CT) exploration for a patient without a well defined epileptic zone ;main sequences (a,b) are showed in this figure.

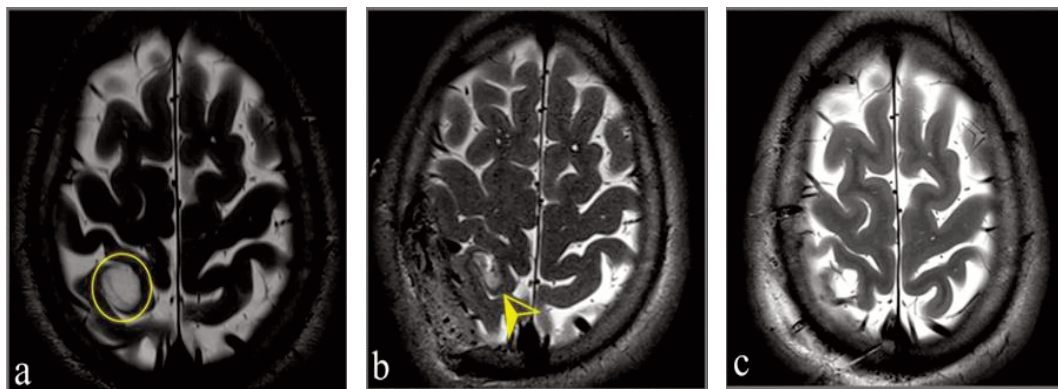


Figure 4 : Axial T2 weighted MRI of a patient with refractory epilepsy operated using intraoperative MRI imaging .a : Pre-operative imaging showing hyper intense T2 lesion close to the right motor cortex.b: Intraoperative imaging ,showing a residual tumoral tissue (yellow arrow head) within the surgical cavity. c: postoperative imaging: complete removal of the tumor. Histology was concomitant with a DNET.

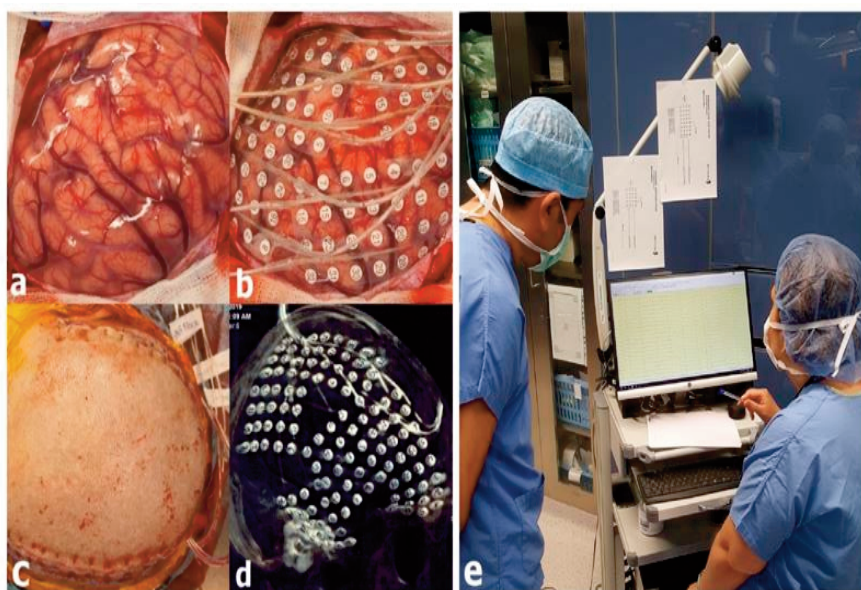


Figure 5 : Images of Electrocoorticography (ECoG)(intraoperative monitoring) using subdural grids . a:surgical exposure of the right cerebral hemisphere(large craniotomy). b: subdural grids insertion for monitoring with the presence of neurology team to guide the right positioning of grids (image e). c: final view after skin closure .Notice the cables of subdural grids through the cutaneous flap.d: Lateral skull X rays of the patient showing the location of grids on the right hemisphere

POST-OPERATIVE MANAGEMENT FOLLOW-UP:

All operated patients, stayed 24 hours in the pediatric intensive care unit, then 3 to 4 days in the patient wards. The antiepileptic treatment was kept in the same doses of the preoperative period.

FOLLOW UP:

Both pediatric neurosurgeons and epileptologist evaluated patients in the following chronology: every 3 months for the first year, every 6 months for the second one, then once a year thereafter. The EEG was performed 3 months after surgery for all patients. The doses of AED s were adjusted according to the results of EEG recordings.

Outcome and results analysis :

Seizures severity in the postoperative period was evaluated using Engel's classification system [13, 14]. The statistical analysis concerned the following parameters: Age, sex, age of seizure onset, side of epilepsy surgery (right-left). The analysis process was realized using SPSS 20.

- Median age at seizure onset was 2 years
- Mean duration of seizures (timeline between seizure onset and operation) was 4.3 years (range: 10 days-17 years).

- Median age of patients at the time of operation was 7.3 years (range:3 months-18 years).

THE FREQUENCY OF SEIZURES BEFORE SURGERY WAS:

- daily (>30 seizures/ month) in 70 patients .
- weekly (5–30 seizures/month) in 19 patients.
- monthly (1–4 seizures/month) in 7 patients.

All demographic data of patients and the frequency of epilepsy are summarized in table1.

Total number of patients	n=96
Gender	
Male	n=63 (65.6 %)
Female	n=33 (34.4 %)
Median age at seizure onset	2 years (range: 1 day–15 years)
Mean age at surgery	7.3years (range: 3 months-18 years)
Mean duration of seizure	4.3 years (range: 10days -17 years)
Seizure frequency	
Daily	70 (72.9%) patients
Weekly	19 (19.8%) patients
Monthly	7(7.3%) patients
Median follow-up	4.9 years(range:4 months-13.7 years)

Table1: Demographics of patients group study.

SURGICAL PROCEDURES

- 70 patients (72.9%) had resective epilepsy surgery including 36 patients with lesionectomies and 34 patients with lobectomies .
- 06 patients with lobectomies also had concurrent MSTs.
- 21 patients (21.8 %) had disconnective surgeries; including :

- * 13 patients with functional hemispherotomy
- * 5 patients with hypothalamic hamartoma (HH) disconnection,
- * 2 patients with callosotomy.
- * 1 patient had pure MSTs (figure 6).

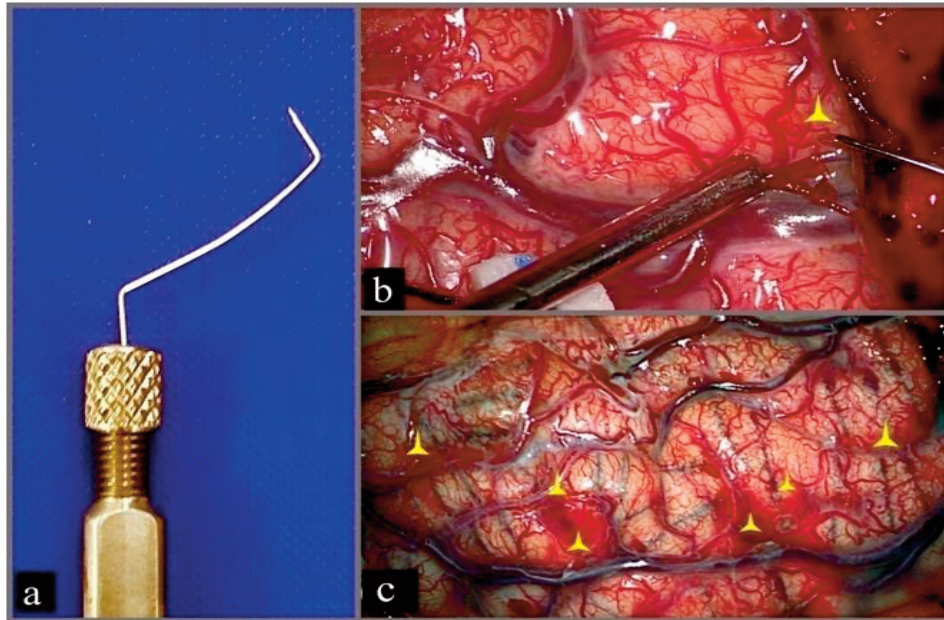


Fig. 6 : : Multiple subpial transection procedure (MST) . a : Morrell needle used in our patients. b: intraoperative microscopic view of a pial transection. Notice the needle's tip (yellow arrow head) close to pia-mater. c : Microscopic view of brain cortex after MST procedure. Multiple locations of transections (yellow arrow head).

- 5 patients had functional epilepsy surgery(vagal nerve stimulator implantation).

All of the surgical procedures are detailed in table 2.

All patients who had a resective surgery, were monitored using ECOG (electrocorticography).

The invasive EEG recording with subdural grids was performed in 12 patients (12.5%).

From the group of resective surgery (70 patients) ; 25 patients had unilobar resection.

These resections concerned: The frontal lobe in 5 patients, temporal lobe in 19 patients and the occipital lobe in 1 patient. In 9 patients, the resection was in a multilobar way. Thirty-six patients had lesionectomies.

Type of surgery	Engel classification				Total
	I	II	III	IV	
Resective surgery, n=70 (70.9%)					
Lesionectomy	26 (74.2%)	6 (17.1%)	3 (8.6%)	1 (2.9%)	36 (100%)
Unilobar resection	18 (75%)	3 (12.5%)	2 (8.3%)	2 (8.3%)	25 (100%)
Multilobar resection	4 (44.4%)	2 (22.2%)	3 (33.3%)	0 (0%)	9 (100%)
Disconnective surgery, n=21 (21.8%)					
Callosotomy	0 (0%)	0(0%)	1 (50%)	1 (50%)	2 (100%)
Functional hemispherotomy	7 (53.8%)	3 (23.1%)	2 (15.4%)	1 (7.7%)	13 (100%)
Hypothalamic hamartoma disconnection	4 (80%)	0 (0%)	0 (0%)	1 (20%)	5 (100%)
MST	1(100%)				1(100%)
Functional surgery, n=5 (5.2%)					
Vagal nerve stimulator implantation	0 (0)	0 (0)	3(60%)	2 (40%)	5 (100%)

Table 3: Epilepsy surgery outcome according to surgery types.

The etiological distribution in the group of patients that had functional hemispherotomy, was as follows : Sturge-Weber syndrome in 4 patients, Rasmussen encephalitis in 1 patient, and hemispheric infarcts in 2 patients. Since we performed functional hemispherotomies, we did not

send tissue for pathological investigations.

The group of patients with neurocutaneous syndromes included 9 patients : 5 with tuberous sclerosis, and 4 with Sturge-Weber syndrome (figure 7; illustrates one case of Sturge-Weber syndrome).

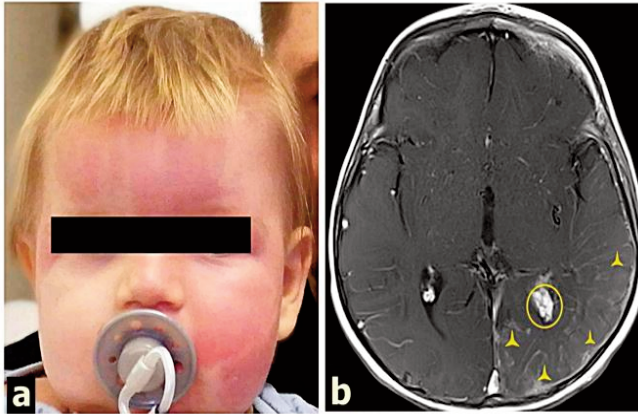


Figure 7 : Clinical and radiological presentation of Sturge-Weber syndrome; called also encephalo-trigeminal angiomatosis. a :Child's face with a pathognomonic left sided facial birthmark related to capillary malformations in the regions of the forehead and left cheek .b: Axial T1+gadolinium MRI sequence of the same patient showing a hypertrophic choroid plexus (yellow circle) and multiples enhancements in sulci (yellow arrow head).

Common complications of neurosurgical procedures such as intraparenchymal, epidural, subdural hematomas were not observed in our study, except one case who had invasive subdural grid monitoring developed brain abscess.

The longest period for deficit resolution was 9 Months. All of the hemispherotomy patients had preoperative hemiparesis and only three of them had worsening of a hemiparesis. We noticed a contralateral visual deficit in one case.

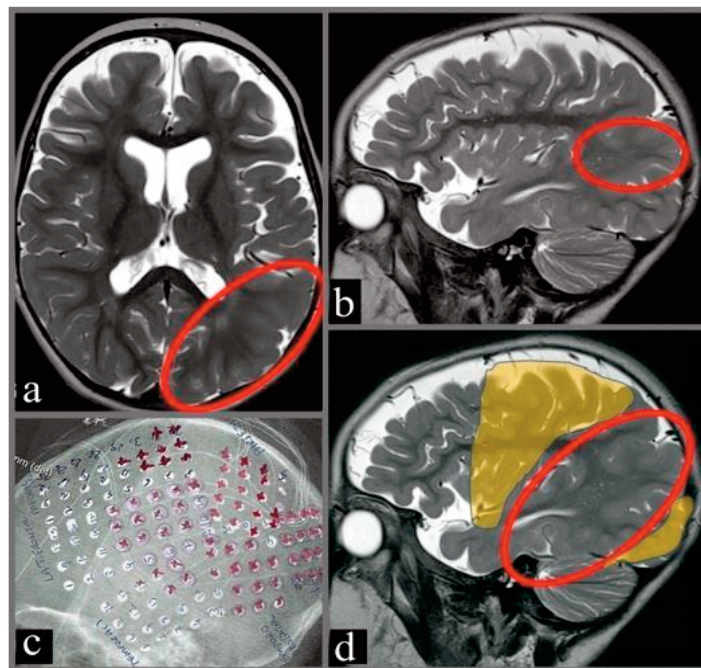


Figure 8 : Patient with refractory epilepsy. a: Axial T2 MRI sequence showing the signal abnormalities in the left parietal and occipital hemisphere (red circle). b: Sagittal T2 weighted images showing the same appearance. (red circle). c: Lateral skull X rays of subdural grid insertion for electric activity monitoring .d: Yellow field plus red circle designates the subdural grid proven epileptic foci. Red circle indicates the area that we decided to remove before we performed invasive grid monitoring. Yellow area indicates the abnormal epileptic foci that we would skip if we did not perform invasive grid before resective surgery.

Results of available histological studies (69 cases) were concomitant with the following diagnosis: pure cortical dysplasia in 24 patients (25 %) and associated with Other lesions (DNET, tubers...) in 6 patients, low-grade tumors (DNET , gangliogliomas and astrocytomas)in 20 patients , hypothalamic hamartoma in 5 patients (5.2%) and finally other pathologies (tubers, gliosis, cavernomas, pial angiomas and gliosis) in 11 patients.

The post-operative median follow-up in our study is 4.9 years (range: 4 months-13.7 years). Post-operative evaluation using

Engel classification system revealed following results:

- Engel class 1: 60 Patients (62.5%).
- Engel class 2: 14 Patients (14.5%).
- Engel class 3: 14 Patients (14.5%).
- Engel class 4: 08 patients (8.33%).

The table 3 summarizes the outcome of seizures in all surgical procedures according to Engel classification.

Our pediatric epileptologist discontinued AEDs in 22 patients and reduced them in 39 patients.

Type of surgery	Engel classification				Total
	I	II	III	IV	
Resective surgery, n=70 (70.9%)					
Lesionectomy	26 (74.2%)	6 (17.1%)	3 (8.6%)	1 (2.9%)	36 (100%)
Unilobar resection	18 (75%)	3 (12.5%)	2 (8.3%)	2 (8.3%)	25 (100%)
Multilobar resection	4 (44.4%)	2 (22.2%)	3 (33.3%)	0 (0%)	9 (100%)
Disconnective surgery, n=21 (21.8%)					
Callosotomy	0 (0%)	0(0%)	I (50%)	1 (50%)	2 (100%)
Functional hemispherotomy	7 (53.8%)	3 (23.1%)	2 (15.4%)	1 (7.7%)	13 (100%)
Hypothalamic hamartoma disconnection	4 (80%)	0 (0%)	0 (0%)	1 (20%)	5 (100%)
MST	1(100%)				1(100%)
Functional surgery, n=5 (5.2%)					
Vagal nerve stimulator implantation	0 (0)	0 (0)	3(60%)	2(40%)	5 (100%)

Table 3: Epilepsy surgery outcome according to surgery types.

CONCLUSIONS OF STATISTICAL ANALYSIS:

1- The surgical outcome was completely independent of these parameters: age, sex, histological diagnosis, age at surgery, length of epilepsy period until surgical management, side of surgery and frequency of seizures.

2- Resective surgery was the most efficient modality in controlling seizures;

including lesionectomies with best rates , followed by unilobar resections.

3- The earlier onset of seizures is associated with poor control of epilepsy, comparing with later occurrences.

4- The most common etiology of epilepsy in earlier ages is cortical dysplasia, in comparison to older patients.

DISCUSSION

Epilepsy is one of the most frequent neurological diseases in children. Its prevalence demonstrates strongly the significant extent of this pathology in the world. Nearly 10.5 million children are epileptic, which represent a quarter of all patients with epilepsy. Among this group of patients; until 14% will develop intractability to different treatments (1, 15, 26). Several studies demonstrated that the refractoriness of seizures was associated with multiples factors such as: age at onset, frequency of seizures and past medical history of neonatal epilepsy (9, 24, 26). The first line of treatment of epilepsy is mainly antiepileptic drugs.

Although this medication is effective in reducing the number and frequency of seizures, it does not remain without risks for the fetus. Several teratogenic effects have been described in the literature, among which we can mention the neural tube defects, some digital malformations, and facial clefts (8, 16, 22).

The immature brain of young children seems to be vulnerable to elongated cures and elevated doses of AED. This therapy may induce apoptotic neurodegeneration and disrupts processes of neuronal cells such as proliferation, migration and organization (16). In addition to this, chronic seizures can lead to serious problems on learning, mental development, behavior and memory functions in a child's brain (7, 30).

Consequently, the management of epileptic children has been completely modified. Currently, surgical treatment is favored as a therapeutic modality to circumvent the harmful effects of drugs and epilepsy itself on the brain regardless the patient's age in drug resistant epilepsy (25).

One of the subjects discussed by the ILAE about concerns of epilepsy surgery was the indication, mentioning that candidates for surgery must include mainly children with the persistence of seizures despite a strictly conducted antiepileptic treatment and those complaining of important disabling side effects of drugs. Another consideration was quoted about patients without a well-defined electro-clinical profile. This group must be assessed in a pediatric specialized center and may join surgical candidates (11). In the same guidelines (11), the preoperative assessment must contain:

1- Brain MRI with a specific epilepsy protocol and in few circumstances a brain CT to evaluate calcifications.

2- Functional imaging including; FMRI

and PET or SPECT (single photon emission CT) if available.

3- Electroencephalography (EEG) with interictal scalp EEG, video EEG and in some cases subdural EEG (invasive exploration).

4- Neuropsychological assessment is mandatory.

All the steps of this recommended protocol were strictly followed in all patients of our study. The MRI was performed according to the epilepsy protocol and included functional and tractography sequences. Video EEG recording was also conducted at least for two days.

Once the exploration was achieved, the decision was made with the participation of the entire team members including: a pediatric neurosurgeon, epileptologist and a neuroradiologist.

After a full analysis of our statistical results, we concluded that an earlier onset of seizures is an indicator of unfavorable prognosis in the post-operative period. This finding was also reported in the literature by other authors (10, 28).

Furthermore, the early onset of seizures can be a major predictor of intractability in infantile seizures (6). This characteristic of seizures is related to the different effects of epilepsy on the growing and immature child's brain. These early changes are represented by the organization of epileptogenic networks, which will be at the origin of an increased ability to maintain this pathology in the future for the same patient (5, 27).

This consequence is almost missing in the adult's brain where these connections were already well established (10).

In our study, the best results in reducing seizure's severity were observed in the group of patient that had resective procedures as surgical technique (70 patients).

Among this, candidates with lesionectomies (36 patients) had the most favorable prognosis followed by those that had unilobar (34 patients) or multilobar resections. Several studies reported the same results about relieving seizures using resective epileptogenic zone as surgical modality (17, 28, 31).

Our study showed also those following parameters: age at the moment of surgery, sex, histological diagnosis, frequency of seizures, duration of epilepsy before surgery and the side of surgery, were independent of the postoperative epileptic course and its prognosis. However in one study (17), the etiological histology of epilepsy was a

determinant factor in seizure control. They reported that cortical dysplasia was an unfavorable indicator of seizure's relief after resection because of the blurred limits of this malformation and the wide extent of the epileptic network in children (17).

In the present series, the most favorable prognosis was observed in patients that had surgical resection of neoplasm's. This figure is similarly described by other authors (17, 19, 31). For our patients, the difference between outcomes; after tumoral resections and other pathologies was not significant because of the reduced size of our population study.

Epilepsy surgery for children appears to be valuable and an effective therapeutic modality with rare morbidity and no mortality (17, 29, 31). For our group of patients only 3 had permanent hemiparesis after surgery all of whom had hemispherotomy procedures.

One of the aims of pediatric epilepsy surgery is to reduce or to discontinue AED for patients. This perspective is desirable to circumvent the harmful effects of this medication on the development of a child's brain and also lower the economic cost of these drugs for institutions and countries. In our study, medication was discontinued in 22 and reduced in 39 patients.

CONCLUSION

Refractory epilepsy has detrimental effects on the immature brain of a child. Surgical treatment remains an effective modality without mortality in patients with drug resistant epilepsy. Early onset seizures are associated with poor prognosis. Better outcomes were reported in candidates of resective surgery. Surgical outcome is independent of age at surgery, sex, histological diagnosis, length and frequency of epilepsy.

REFERENCES

- ARTS WF, BROUWER OF, PETERS AC, STROINK H, Course and prognosis of childhood epilepsy: 5-year follow-up of the Dutch study of epilepsy in childhood. *Brain* 127:1774-1784, 2004
- BAILEY EE, PFEIFER HH, THIELE EA: The use of diet in the treatment of epilepsy. *Epilepsy Behav* 6:4-8, 2005
- BARAÑANO KW, HARTMAN AL: The ketogenic diet: uses in epilepsy and other neurologic illnesses. *Current treatment options in neurology* 10:410-419, 2008
- BARBORKA CJ: Ketogenic Diet treatment of epilepsy in adults. *Journal of the American Medical Association* 91:73-78, 1928
- BEN-ARI Y, HOLMES GL: Effects of seizures on developmental processes in the immature brain. *Lancet Neurol* 5 : 1055-1063, 2006
- BERG AT, LEVY SR, NOVOTNY EJ, SHINNAR S: Predictors of intractable epilepsy in childhood: a case-control study. *Epilepsia* 37:24-30, 1996
- BESAG FM: Childhood epilepsy in relation to mental handicap and behavioural disorders. *J Child Psychol Psychiatry* 43:103-131, 2002
- BUEHLER BA, DELIMONT D, VAN WAES M, FINNELL RH: Prenatal prediction of risk of the fetal hydantoin syndrome. *N Engl J Med* 322:1567-1572, 1990
- CHAWLA S, ANEJA S, KASHYAP R, MALLIKA V: Etiology and clinical predictors of intractable epilepsy. *Pediatr Neurol* 27:186-191, 2002
- COSSU M, LO RUSSO G, FRANCIONE S, MAI R, NOBILI L, SARTORI I, TASSI L, CITTERIO A, COLOMBO N, BRAMERIO M, GALLI C, Epilepsy surgery in children: results and predictors of outcome on seizures. *Epilepsia* 49:65-72, 2008
- CROSS JH, JAYAKAR P, NORDLI D, DELALANDE O, DUCHOWNY M, WIESER HG, Proposed criteria for referral and evaluation of children for epilepsy surgery: recommendations of the Subcommittee for Pediatric Epilepsy Surgery. *Epilepsia* 47:952-959, 2006
- D'ANDREA MEIRA I, ROMÃO TT, PIRES DO PRADO HJ, KRÜGER LT, PIRES MEP, DA CONCEIÇÃO PO: Ketogenic Diet and Epilepsy: What We Know So Far. *Frontiers in neuroscience* 13:5-5, 2019

13. ENGEL JR J: Update on surgical treatment of the epilepsies. *Clinical and experimental neurology* 29:32, 1992
14. ENGEL JR J, LEVESQUE M, SHIELDS W: Surgical treatment of the epilepsies: presurgical evaluation. *Clinical neurosurgery* 38:514, 1992
15. GUPTA A: *Epilepsy In Children*, 2nd Edition. *Neurology* 64 : 1489-1489, 2005
16. IKONOMIDOU C, TURSKI L: Antiepileptic drugs and brain development. *Epilepsy Res* 88: 11-22, 2010
17. KIM SK, WANG KC, HWANG YS, KIM KJ, KIM IO, LEE DS, YI Y, CHO BK: Pediatric intractable epilepsy: the role of presurgical evaluation and seizure outcome. *Childs Nerv Syst* 16 : 278-285; discussion 286, 2000
18. KOTSOPOULOS IA, VAN MERODE T, KESSELS FG, DE KROM MC, KNOTTNERUS JA: Systematic review and meta-analysis of incidence studies of epilepsy and unprovoked seizures. *Epilepsia* 43:1402-1409, 2002
19. KRAL T, KUCZATY S, BLUMCKE I, URBACH H, CLUSMANN H, WIESTLER OD, ELGER C, SCHRAMM J: Postsurgical outcome of children and adolescents with medically refractory frontal lobe epilepsies. *Childs Nerv Syst* 17:595-601, 2001
20. KWAN P, ARZIMANOGLU A, BERG AT, BRODIE MJ, ALLEN HAUSER W, MATHERN G, MOSHE SL, PERUCCA E, WIEBE S, FRENCH J: Definition of drug resistant epilepsy: consensus proposal by the ad hoc Task Force of the ILAE Commission on Therapeutic Strategies. *Epilepsia* 51:1069-1077, 2010
21. LIU H, YANG Y, WANG Y, TANG H, ZHANG F, ZHANG Y, ZHAO Y: Ketogenic diet for treatment of intractable epilepsy in adults: A meta-analysis of observational studies. *Epilepsia Open* 3:9-17, 2018
22. MEADOR KJ, BAKER G, COHEN MJ, GAILY E, WESTERVELD M: Cognitive/behavioral teratogenic effects of antiepileptic drugs. *Epilepsy & behavior : E&B* 11 : 292-302, 2007
23. NEAL EG, CHAFFE H, SCHWARTZ RH, LAWSON MS, EDWARDS N, FITZSIMMONS G, WHITNEY A, CROSS JH: The ketogenic diet for the treatment of childhood epilepsy: a randomised controlled trial. *Lancet Neurol* 7:500-506, 2008
24. OHTSUKA Y, YOSHINAGA H, KOBAYASHI K: Refractory childhood epilepsy and factors related to refractoriness. *Epilepsia* 41 Suppl 9:14-17, 2000
25. RYVLIN P, CROSS JH, RHEIMS S: Epilepsy surgery in children and adults. *Lancet Neurol* 13:1114-1126, 2014
26. SEKER YILMAZ B, OKUYAZ C, KOMUR M: Predictors of intractable childhood epilepsy. *Pediatr Neurol* 48:52-55, 2013
27. STAFSTROM CE, LYNCH M, SUTULA TP: Consequences of epilepsy in the developing brain: implications for surgical management. *Semin Pediatr Neurol* 7:147-157, 2000
28. TANRIKULU B, IŞIK U, ÖZEK MM: Epilepsy Surgery in Pediatric Patients: A Single-Center Experience. *Epilepsi* 25:27-34, 2019
29. TANRIKULU B, ÖZEK MM (2019) Epilepsi Cerrahisi. In: Apak S, Tatlı B (eds) Apak ve Tatlı Pediatrik Epileptoloji. Nobel Tıp Kitabevleri İstanbul, pp 221-238
30. TANRIKULU B, ÖZEK MM: Surgical Outcome of Pediatric Patients with Hypothalamic Hamartoma (In Press). *Epilepsi* 2020
31. WYLLIE E, COMAIR YG, KOTAGAL P, BULACIO J, BINGAMAN W, RUGGIERI P: Seizure outcome after epilepsy surgery in children and adolescents. *Ann Neurol* 44:740-748, 1998